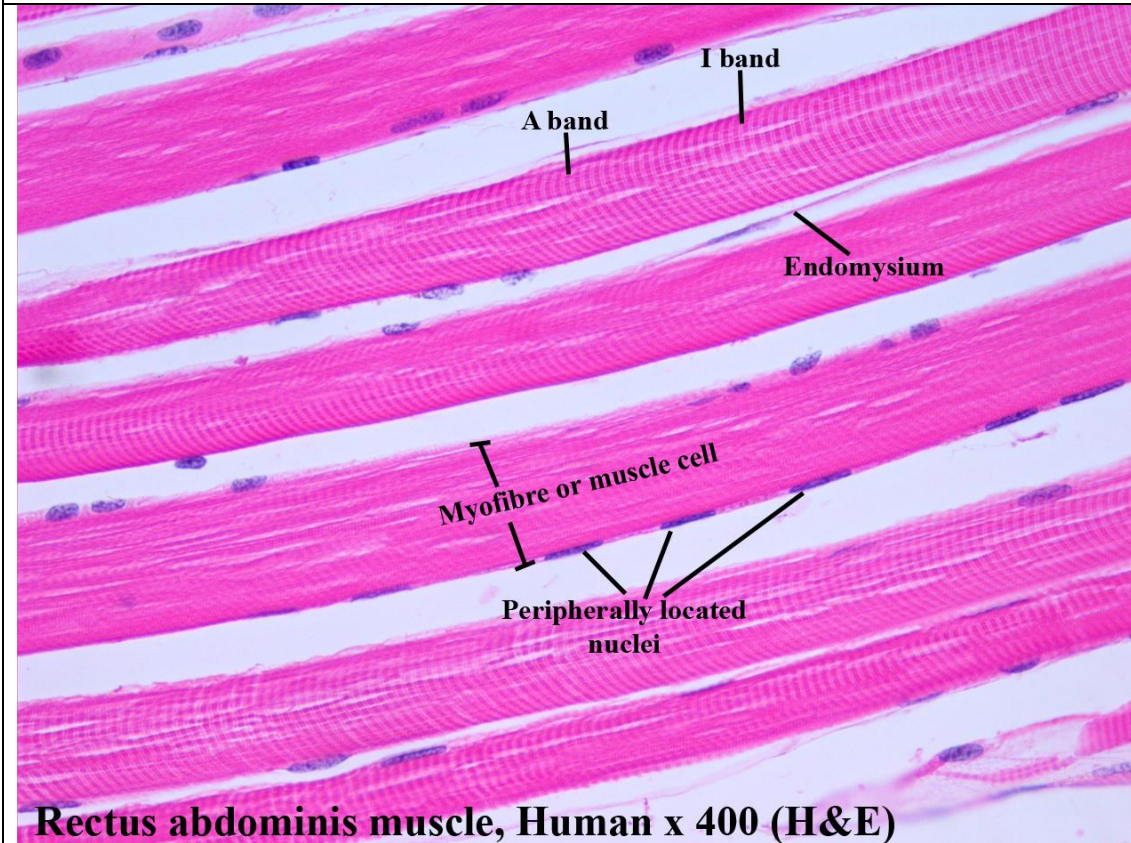
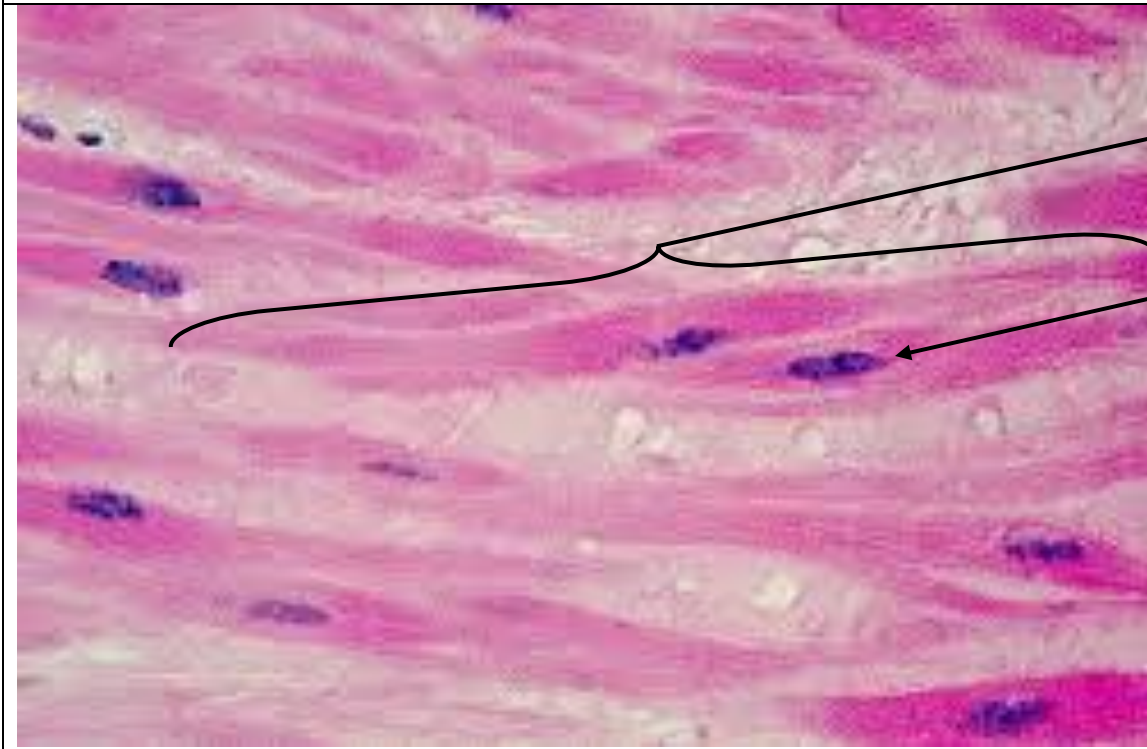

SKELETAL MUSCLE



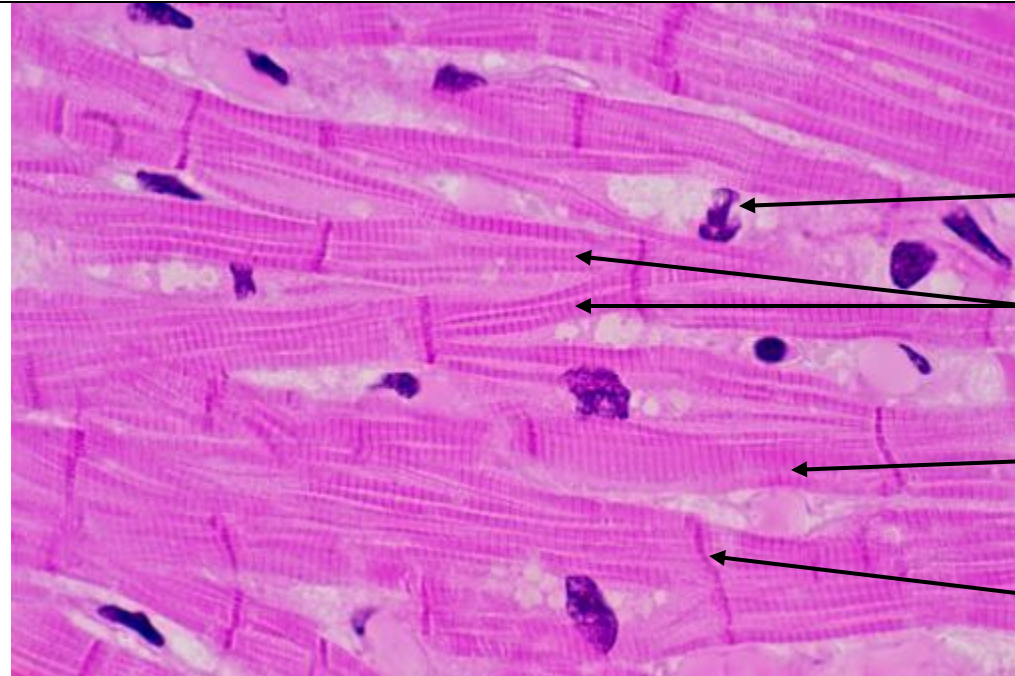
SMOOTH MUSCLE



MUSCLE
Cell

NUCLEUS

CARDIAC MUSCLE



Nucleus

Branching
Fibers

Striations

Intercalated
disks