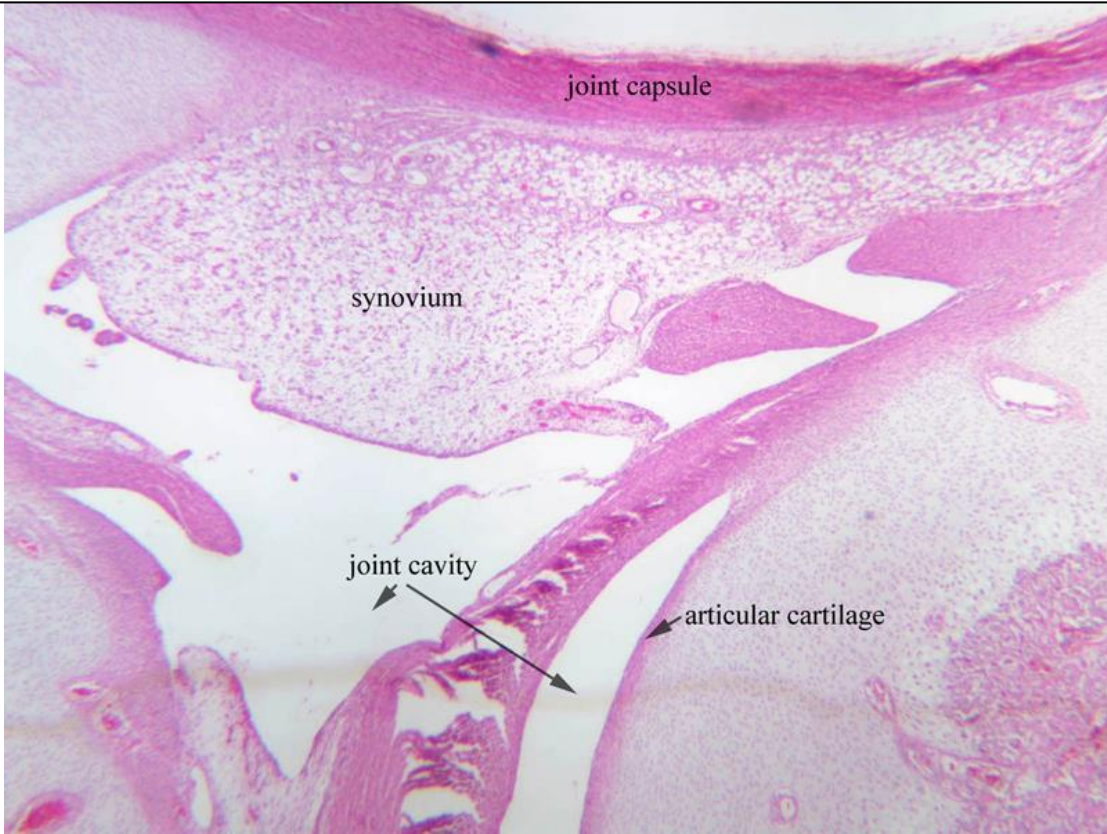
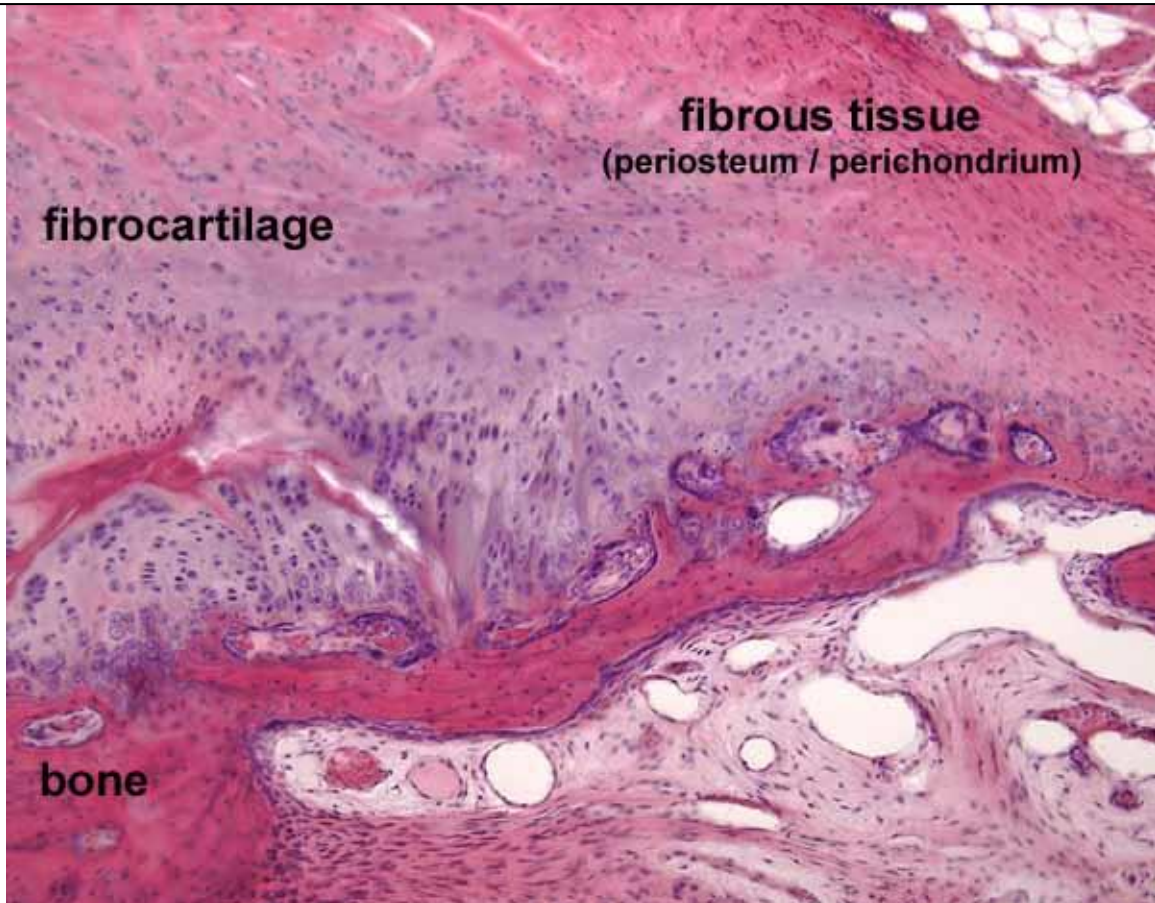


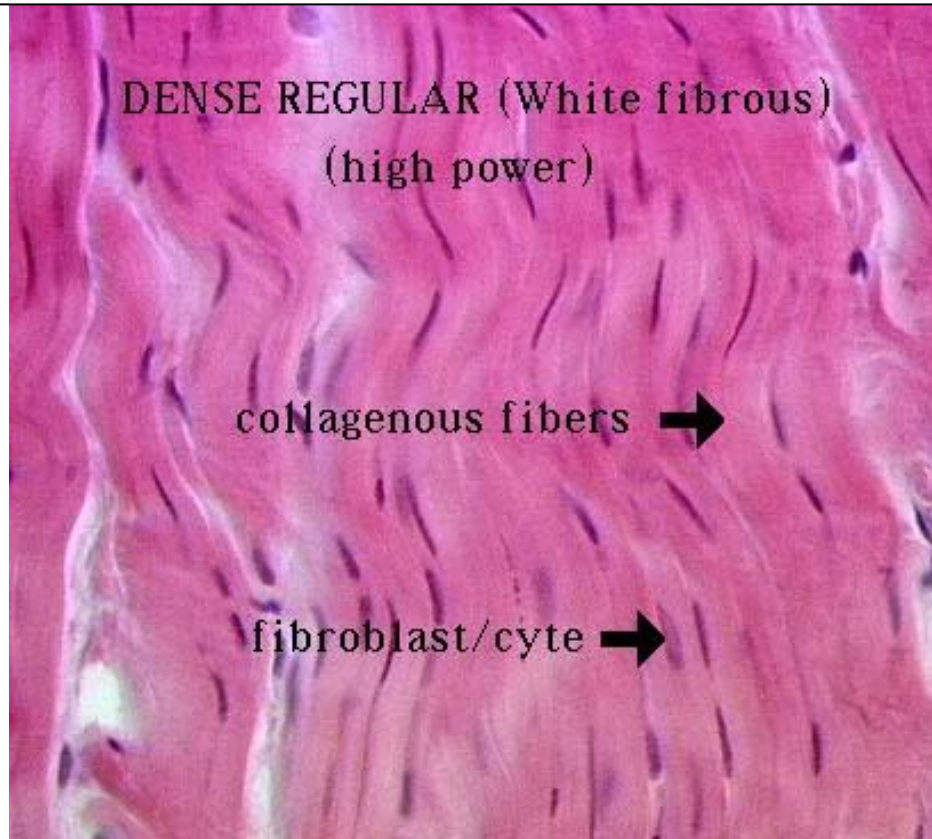SYNOVIAL MEMBRANE – pg 83-84



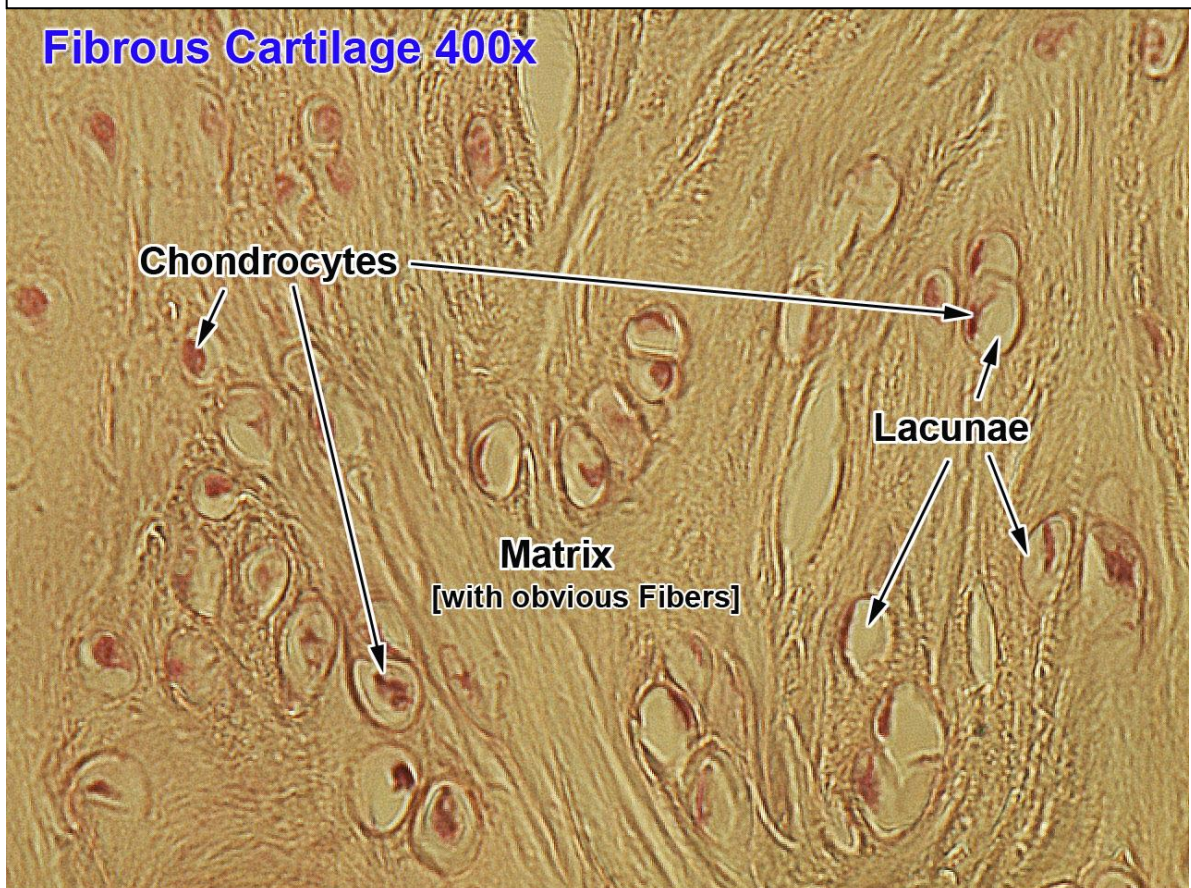
PERIOSTEUM – pg 113



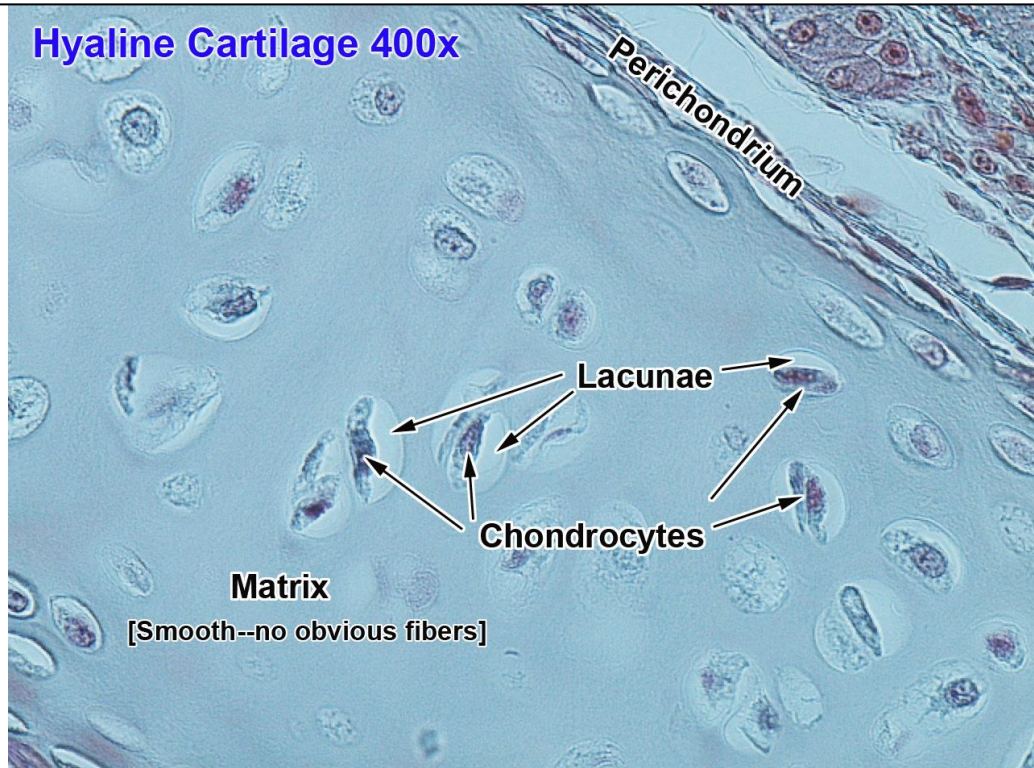
DENSE FIBROUS CONNECTIVE TISSUE – pg 69-70



FIBROCARILAGE – pg 69&71



HYALINE CARTILAGE – pg 69&71



BONE (OSSEUS) TISSUE – pg 69&71

